

## Prurigo nodularis

Sibylle Eigelshoven, Bernhard Homey  
Department of Dermatology, Düsseldorf University Hospital,  
Düsseldorf, Germany

Reviewers: Sonja Ständer, Münster  
and Elke Weisshaar, Heidelberg

### Summary

Prurigo nodularis is a chronic inflammatory skin disorder characterized by severe pruritus and papules and nodules with excoriations and ulcerations due to scratching. Typical lesions develop on clinically healthy or inflamed skin. Accordingly, various dermatological or systemic diseases may cause prurigo nodularis. Associations with atopy, pregnancy, drugs, internal and neurological diseases are frequently observed.

Although little information exists about the pathogenesis of prurigo nodularis, a cascade of events has been identified. The disorder may start with chronic and severe pruritus, which in turn induces mechanical trauma through scratching and subsequently leads to the recruitment of a lymphocyte-rich inflammatory infiltrate, tissue remodeling and the activation as well as proliferation of peripheral nerves.

Prurigo nodularis is difficult to manage and a challenge for any dermatologist. First, any underlying disease should be treated. Nowadays, there are a variety of symptomatic antipruritic drugs available. Hence, the design of individualized treatment protocols based on antipruritic as well as anti-inflammatory approaches is the secondary goal.

### Introduction

Prurigo is derived from the Latin and means “itch”, which simply refers to the common feature shared by all pruriginous diseases, a sometimes intractable pruritus.

Hyde is credited with being the first to describe prurigo nodularis after his report on pruritic nodules on the extensor aspects of the lower extremities in middle-aged women, although the term “prurigo” was already coined in the middle of the 19th century by Ferdinand von Hebra (Hebra 1854; Hyde 1883). Synonyms for prurigo nodularis include prurigo nodularis (Hyde), prurigo simplex chronica, and lichen obtusus corneus (Braun-Falco et al. 2005).

Prurigo nodularis, which was previously believed to be a separate disease entity, is now believed to be a secondary reaction to scratching which is preceded by severe pruritus affecting inflamed or healthy skin. Prurigo nodularis is thus considered a clinical expression of chronic pruritus (Vaidya et al. 2008). In most patients a cause is not identifiable, although there are exceptions, such as for instance in prurigo with underlying systemic disease. In the latter, there is often, however, atopic skin diathesis or atopic dermatitis. Some authors have suggested dividing prurigo nodularis into two forms:

- “early-onset atopic” disease in which the median age of initial manifestation is 19 years and there is a close association with atopic dermatitis and environmental allergens, and
- “late-onset non-atopic” disease in which the median age of initial manifestation is 48 years and there is no association with environmental allergens (Tanaka et al. 1995).

### Epidemiology

Prurigo nodularis affects women more often than men. The disease commonly affects middle-aged or older patients, although it can also occur in children (Amer et al. 2009).

There are no known genetic factors. There are as yet no figures available on the incidence and prevalence of prurigo nodularis.

### Etiopathogenesis

Little is known about the molecular and cellular mechanisms that are responsible for the development of prurigo nodularis. Based on clinical observations and histopathological analyses, the following cascade of events has been identified: severe chronic pruritus leads to repetitive mechanical trauma as a result of scratching, and this chronic skin irritation then leads to a characteristic tissue reaction which is marked by recruitment of a lymphocyte-rich inflammatory infiltrate, activation of epidermal keratinocytes, a circumscribed increase in collagen tissue, and activation and proliferation of peripheral sensory nerves. Over the course of disease this characteristic tissue reaction sustains and exacerbates the pruritus in an amplification cycle that leads to development of the clinical appearance of prurigo nodularis (Fig. 1).

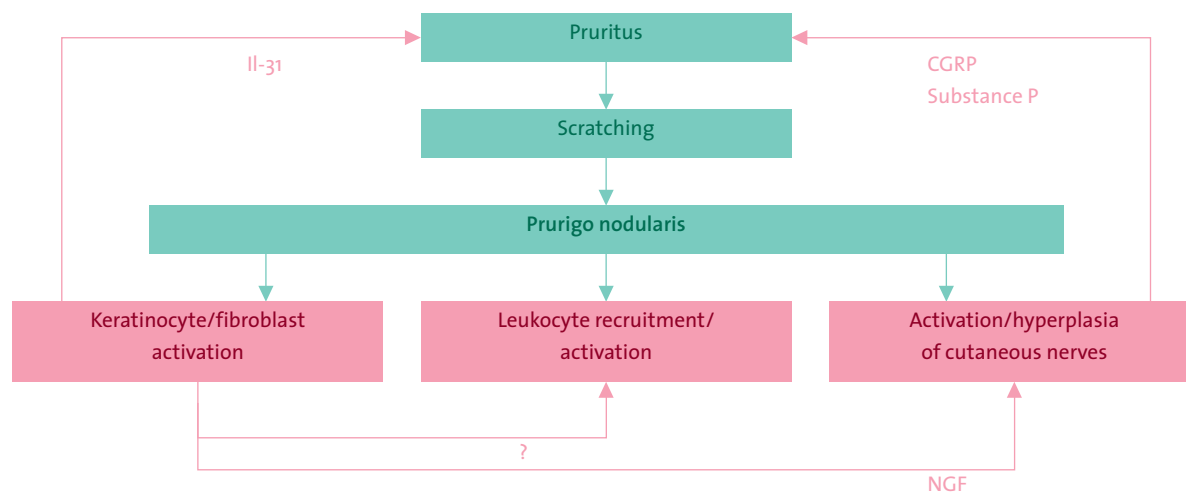


Figure 1: Etiopathogenesis of prurigo nodularis < CGRP: “Calcitonin gene-related peptide”; IL: Interleukin; NGF: Nerve growth factor

Numerous causes can lead to prurigo nodularis as a clinical expression of chronic pruritus. Based on the guidelines for chronic pruritus (Ständer et al. 2006), Figure 2 shows a modified list of several causes that lead to chronic pruritus and ultimately clinical manifestation of prurigo nodularis.

The mechanisms underlying the development of pruritus have been recently thoroughly elucidated in a review by Metz and Ständer (Metz et al. 2008). In the following we draw on these to focus on scientific findings that have contributed to improved understanding of the tissue reaction underlying prurigo nodularis.

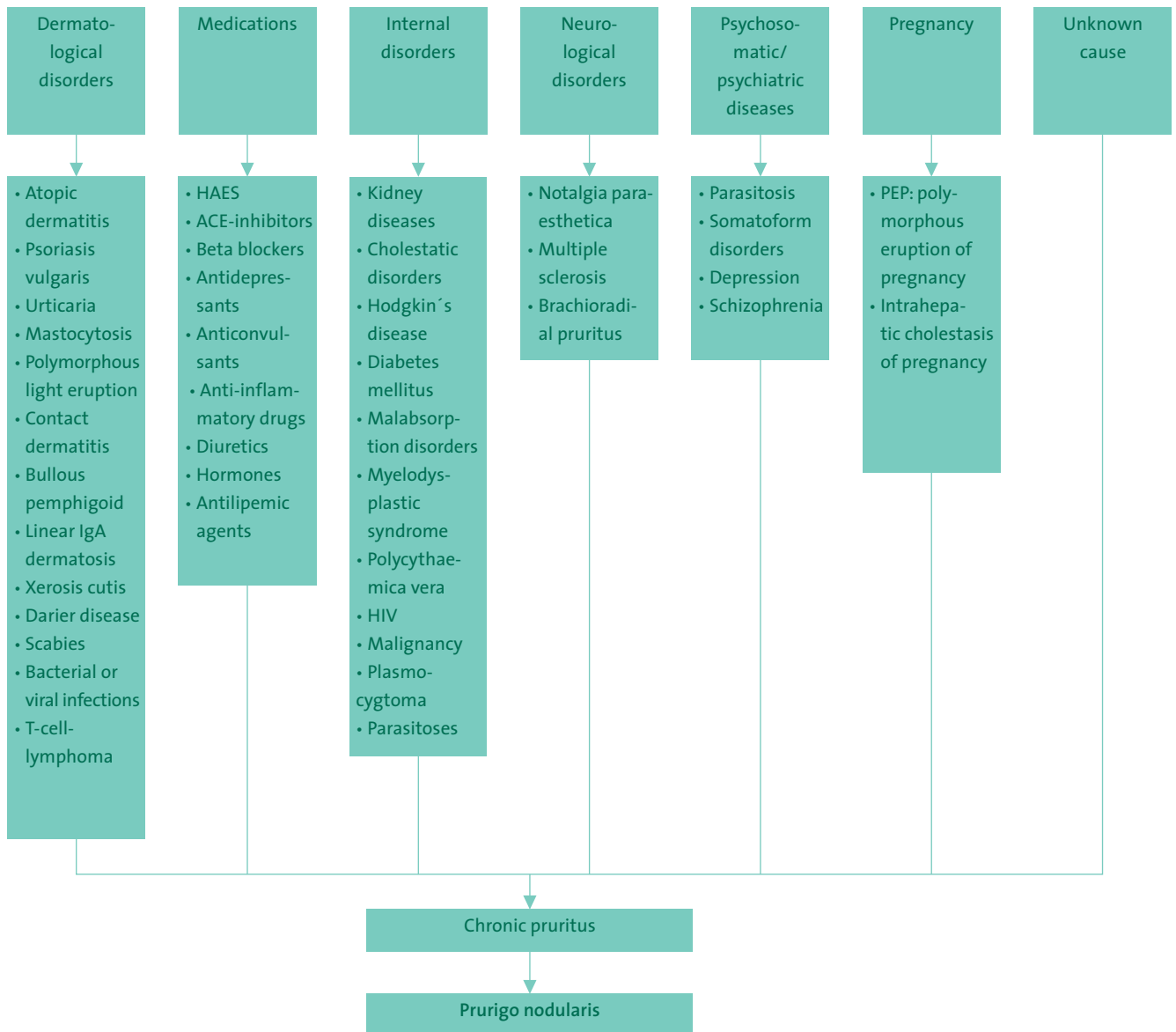


Figure 2: Selected possible causes of prurigo nodularis based on the guidelines for chronic pruritus (Ständer et al. 2006)

### Leukocyte recruitment and activation

The inflammatory infiltrate in prurigo nodularis has been thoroughly described and is known to contain abundant numbers of T lymphocytes, a larger number of dermal dendritic cells, eosinophils, and mast cells. Yet the recruitment pathways of these pathogenetically relevant leukocyte populations are still largely unknown. It may be presumed, however, that after mechanical trauma primary pro-inflammatory cytokines such as interleukin(IL)-1 and tumor necrosis factor alpha (TNF- $\alpha$ ) induce chemokine cascades in keratinocytes. In addition, the association between prurigo nodularis and atopy syndrome suggests that atopy-associated chemokines play a role in the recruitment of effector T cells, eosinophils, and mast cells. Nevertheless, there are still no studies that have described the chemokine signature of prurigo nodularis.

The recent discovery of IL-31 represented the identification of a new cytokine which mediates chronic pruritus under transgenic expression in lymphocytes, which in mice has been shown to lead to dermatitis (Dillon et al. 2004). Subsequent studies showed this new cytokine is found especially in severely itching chronic inflammatory skin disease such as atopic dermatitis and prurigo nodularis and significantly less in psoriatic lesions or in normal skin (Sunkoly et al. 2006). Interestingly, the increase of IL-31 is highest in prurigo nodularis and there are also signs that this cytokine, which is primarily produced by Th2 lymphocytes, mediates pruritus via its receptor that is found on peripheral sensory nerves. Further studies make clear that bacterial superantigens such as staphylococcal enterotoxin-B are potent inducers of IL-31 in leukocytes (Sunkoly et al. 2006). This may be important for the treatment of prurigo nodularis and control of bacterial colonization of lesions as a complementary treatment approach.

A further finding that may be helpful is that along with the increased number of mast cells, the morphology of this cell population is also unusual in prurigo nodularis. Mast cells are enlarged and a subpopulation has a notably dendritic appearance, and they “cluster” near peripheral nerves (Liang et al. 1998). These observations underscore the special role of this cell population in the pathogenesis of prurigo nodularis.

### Keratinocyte and fibroblast activation

Prurigo nodularis involves acanthosis, parakeratosis, and hyperkeratosis of the epidermis (Kerl et al. 2003). These changes are attributed to the chronic stimulation of keratinocytes due to scratching. The underlying molecular mechanisms have not been thoroughly researched.

There are also characteristic changes in the dermis with significant proliferation of collagen tissue, fibroblasts in the papillary dermis, and thick collagen fascicles arranged perpendicularly to the surface. The reasons for this connective tissue proliferation, which is completely reversible under therapy, are still unclear.

### Activation of sensory neurons

Pruritus is the dominant symptom of prurigo nodularis. Histopathological studies show marked hyperplasia of peripheral cutaneous nerves in prurigo nodularis lesions. This activation of sensory nerves leads to increased nerve fiber density (Cowan 1964). Recent studies have shown that peripheral nerves in prurigo nodularis lesions have increased amounts of nerve growth factor (NGF)-receptor p75 (Liang et al. 1996). In addition, skin-infiltrating leukocytes near these peripheral nerves produce high levels of NGF (Johansson et al. 2002). Other studies have underscored that the cutaneous nerves in prurigo nodularis produce much larger amounts of neuropeptides such as “calcitonin gene related peptide” (CGRP) and substance P (Abadia et al. 1992).

A further study has shown that the vanilloid receptor, subtype 1 (VR1/TRPV1), an ion channel, binds to capsaicin, is found in much higher levels on cutaneous nerves in lesional skin in prurigo nodularis patients. Under topical therapy with capsaicin, CGRP and substance P in cutaneous nerves dropped significantly (Ständer et al. 2004).

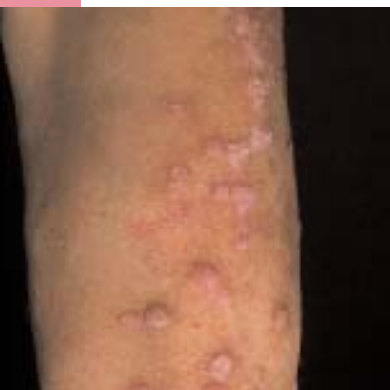These results show that activation and proliferation of cutaneous nerves in patients with prurigo nodularis are associated with increased production of the neuropeptides CGRP and substance P possibly intensifying the pruritus via neurogenic inflammatory pathways.

### Clinical presentation

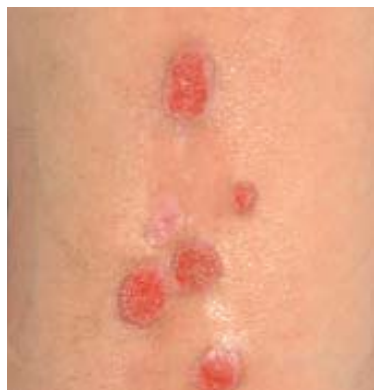The primary symptom with which patients present is usually massive, and sometimes excruciating pruritus. There is usually a symmetrical pattern of involvement, mainly on the extensor aspects of the extremities, the shoulders, and the chest and sacral regions with the appearance of typical lesions (Fig. 3). The face, palms of the hands, and plantar surfaces of the feet are usually not affected and there is never involvement of the mucous membranes.

The primary lesion manifests as a sharply demarcated, tough, mildly erythematous nodule. It can measure up to several centimeters in diameter.

As a result of excruciating pruritus, patients often scratch intensely leading to gray or purple and sometimes verruciform keratotic areas, excoriations, crater-like ulcerations, and hemorrhagic crusts (see Fig. 4).



3



4

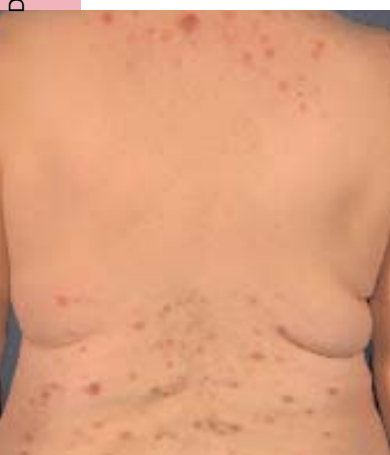Figure 3: Prurigo nodules on the extensor aspects of the left forearm

Figure 4: Secondary lesions in prurigo nodularis: Excoriations, crater-like ulcerations, and scarring

After the lesions heal, residual lesions are left behind with post-inflammation hyperpigmentation or areas of hypopigmentation and scarring.

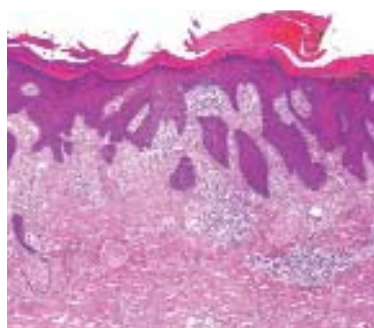
The number of lesions can range from a few solitary lesions to hundreds of lesions.

The skin between individual lesions is generally normal, but there is sometimes xerosis cutis. The development of nodules first occurs as a result of intense scratching. Typically there is an area of skin that is unaffected which the patient cannot reach, such as the middle of the back. This characteristic feature of prurigo nodularis is referred to as the “butterfly sign” and underscores the significance of the mechanical trauma for the development of characteristic lesions (Fig. 5).



5

Figure 5: Characteristic “butterfly sign”: an area of the skin that is unreachable, such as the middle of the back, is free of lesions (as shown here mainly secondary lesions and residual lesions)



6

Figure 6: Histology of a prurigo nodule under 5-fold magnification

The development of areas of keratosis, excoriation, and ulceration on primary lesions is attributed to the constant irritation caused by scratching. The “scratching” of a lesion produces only temporary relief from pruritus, which quickly starts again, leading to an “itch-scratch-cycle” which causes the nodules to persist and leads to secondary lesions.

Due to the simultaneous appearance of recent and older lesions, patients usually present with a polymorphous appearance consisting of recent nodules, excoriations, or crater-like ulcerations and residual lesions such as areas of hypopigmentation or hyperpigmentation as well as scarring.

### Histopathology

Under marked hyperkeratosis with focal parakeratosis there is also irregular acanthosis. The appearance of pseudocarcinomatous or pseudoepitheliomatous hyperplasia arises from variously severe papillomatosis and an irregular, downward proliferation of epidermis and epithelia of adnexal structures.

In the papillary dermis there are increased amounts of multinucleated fibroblasts as well as thick collagen fiber bundles arranged perpendicularly to the surface. Proliferation of nerve fibers and Schwann cells may be observed. In some areas there are dilated, vertically-oriented capillaries. At the surface, around vessels and in interstitial spaces there is a moderately dense infiltrate of lymphocytes, isolated eosinophilic granulocytes, mast cells, macrophages, dermal dendritic cells, melanophages, or hemosiderophages with extravasal erythrocytes. Eosinophilic granulocytes with degranulation may also be found in patients with accompanying atopic diathesis. If there are erosions or excoriations, crusting around the margin with exudation and parakeratosis are typically seen and there are plasma cells and neutrophils (Kerl et al. 2003).

### Differential diagnoses

Definitive diagnosis of prurigo nodularis is usually possible. It is not unusual, however, to see prurigo-like papules as an expression of other skin disorders. The main differential diagnosis is prurigo-like atopic dermatitis. In rare instances, allergic contact dermatitis should be considered (Ido et al. 2008).

Other differentials include chronic inflammatory skin diseases such as lichen ruber verrucosus.

Especially when ruling out bullous disorders such as the prurigo form of bullous pemphigoid or linear IgA dermatosis, along with dermatohistopathological tests, additional diagnostic procedures such as direct and indirect immunofluorescence studies may be useful (Gallo et al. 1993; Massa et al. 1982; Roenigk et al. 1986; Ross et al. 1992; Tani et al. 1989; Torchia et al. 2006).

A selection of differential diagnosis is listed in Table 1.

**Table 1: Differential diagnoses in prurigo nodularis**

<b>Eczematous diseases</b>	<ul style="list-style-type: none"> <li>• atopic dermatitis</li> <li>• allergic contact dermatitis</li> </ul>
<b>Chronic inflammatory disorders</b>	<ul style="list-style-type: none"> <li>• Lichen ruber verrucosus</li> </ul>
<b>Autoimmune diseases</b>	<ul style="list-style-type: none"> <li>• Lupus erythematoses hypertrophicus et profundus</li> </ul>
<b>Bullous disorders</b>	<ul style="list-style-type: none"> <li>• bullous pemphigoid</li> <li>• Pemphigoid nodularis</li> <li>• Dermatitis herpetiformis</li> <li>• Linear IgA dermatosis</li> </ul>
<b>Tumors</b>	<ul style="list-style-type: none"> <li>• Cutaneous metastases</li> <li>• Lymphoma</li> <li>• Pseudolymphoma</li> <li>• Dermatofibroma</li> <li>• Keratoacanthoma</li> </ul>
<b>Other diseases</b>	<ul style="list-style-type: none"> <li>• Pruritic papules in HIV</li> <li>• Ictus reactions</li> <li>• Polymorphous light eruption (Prurigo aestivalis)</li> <li>• Actinic prurigo</li> <li>• Prurigo pigmentosa</li> </ul>

### Diagnosis

Given that the development of nodules in prurigo nodularis is presumably a secondary reactive response to persistent scratching to relieve pruritus, an underlying pruritic disorder must be ruled out, consistent with chronic pruritus. This includes skin disorders as well as endocrine and metabolic disorders, hematological and lymphoproliferation diseases, infectious diseases, parasitic diseases, and neurological and psychogenic diseases. In addition, certain medications can cause and sustain pruritus.

**! Often, despite extensive diagnostic testing, the cause of disease remains uncertain !**

Step-by-step diagnosis of prurigo nodularis is possible based on the AWMF guidelines for chronic pruritus (Ständer et al. 2006). An algorithm for diagnosis is presented in Figure 7.

Diagnosis is based on the taking of a thorough family history and careful clinical examination.

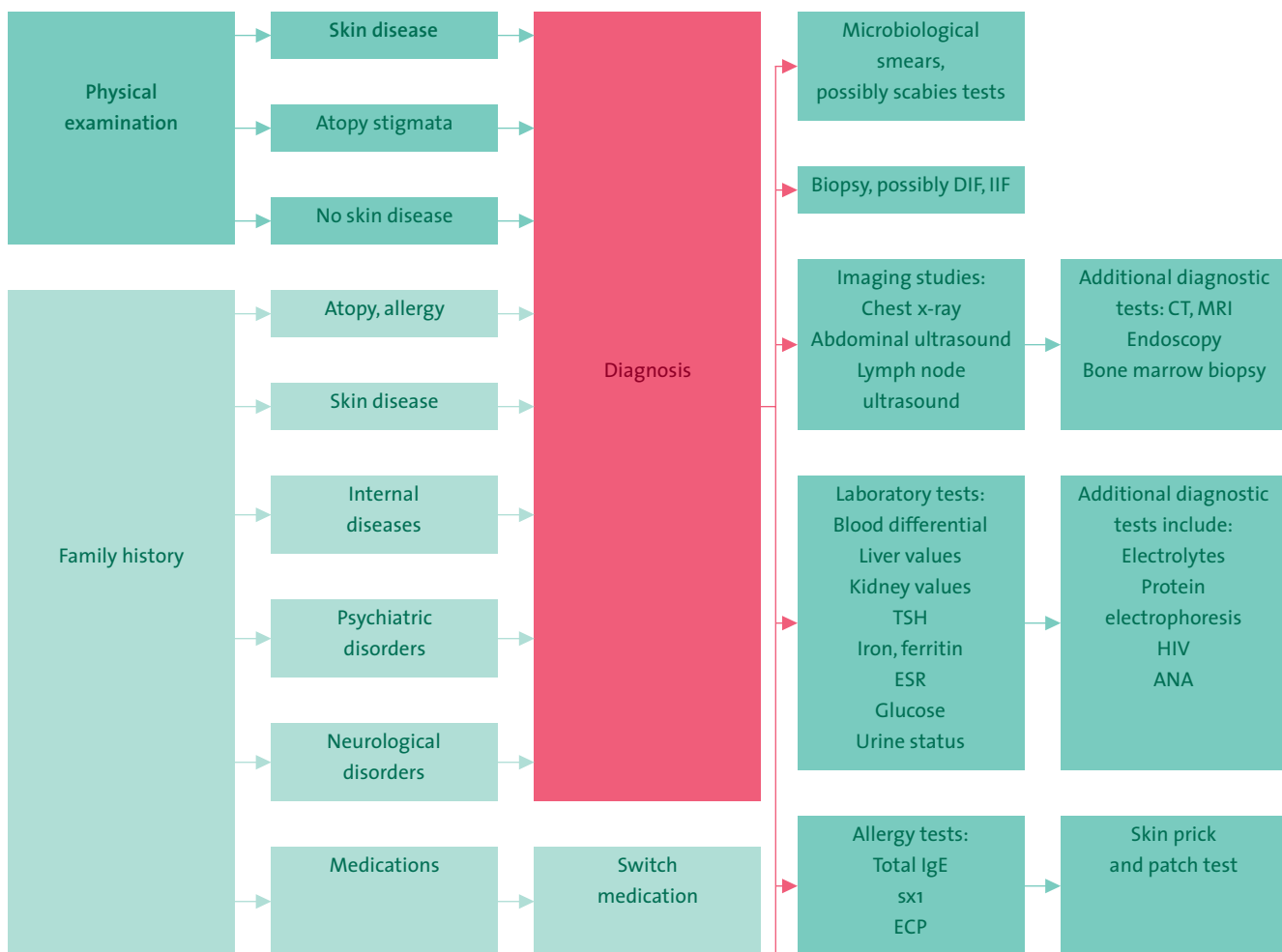
To rule out other skin diseases with pruriginous appearances, histopathological analysis is recommended. If there are clinical signs, bacteriological and mycological smears as well as scabies tests are advised.

Preliminary chemical laboratory testing should be performed along with imaging studies including lymph node sonography of palpable lymph nodes, a chest x-ray, and abdominal ultrasound. Further diagnostic procedures, if needed by a specialist from another field, depends on the results of the family history and the results of basic initial tests.

In order to identify patients with atopic diathesis, the first step is a clinical evaluation based on diagnostic criteria for atopic dermatitis (Brennkmeijer et al. 2008). Laboratory tests can be used to determine total IgE, ECP (“eosinophilic cationic protein”) and sx1 (mixed allergen test: detection of specific IgE antibodies to timothy grass, rye, mugwort, birch, Cladosporium herbarum, house dust mites, and cat or dog dander). Additional allergy tests can be performed depending on the family history and test results. These include skin prick and patch testing (Zelickson et al. 1989) as well as other specific allergy tests.

In patients with prurigo nodularis, psychosomatic and psychiatric diseases should also be excluded as the primary cause of accompanying psychological factors (Schneider et al. 2006a, b).

In patients with prurigo nodularis, if psychosomatic or psychiatric disease is suspected, a psychosomatic specialist or psychiatrist should be promptly consulted for any necessary diagnostic procedures or treatment.



ANA: antinuclear antibodies; ESR: erythrocyte sedimentation rate;  
 CT: computed tomography; DIF: direct immunofluorescence;  
 ECP: eosinophilic cationic protein; HIV: human immunodeficiency virus;  
 IIF: indirect immunofluorescence; MRI: magnetic resonance imaging;  
 sx1: mixed allergen test; TSH: thyroid-stimulating hormone

Figure 7: Diagnostic algorithm in prurigo nodularis based on the AWMF guidelines for chronic pruritus (Ständer et al. 2006)

### Therapy

Therapy of prurigo nodularis is a particular challenge, given that the disorder is highly refractory. The goal of treatment is to use available topical and systemic therapies, as appropriate to the individual patient situation, and to develop an individual treatment scheme.

Except for case reports and case series, there are no randomized clinical studies on the treatment of prurigo nodularis. The therapy options listed below are primarily off-label therapies which should only be administered after carefully considering the risk-to-benefit ratio and after thoroughly educating the patient and possibly obtaining written consent.

Causal therapy of prurigo nodularis mainly consists of careful diagnosis and extensive testing and examination of the patient to detect and eliminate all causes that could be underlying pruritus (e.g., internal or neurological disorders). Therapy is specific to the underlying disorder.

If causal therapy cannot sufficiently reduce or stop the symptoms of pruritus, or if no cause can be found, the main goal of treatment is to quickly interrupt the chronic pruritus, which is seen as the initiating factor and the one that sustains prurigo nodularis. The therapies listed below are symptomatic treatments that are antipruritic agents.

The therapy recommendations of the AWMF guidelines for pruritus (Ständer et al. 2006) can be followed for treatment. There are also therapy options that are used especially for prurigo nodularis.

First, the patient should be thoroughly informed about the disease including the difficulty in successfully treating it. In terms general measures, it is especially important to tell patients of the necessity of intense and regular use of emollients given that even just xerosis cutis can cause pruritus to persist. Consistent use of a moisturizer in patients with atopic diathesis or with known or existing atopic dermatitis is especially important. If there are excoriations and ulcerations due to scratching, topical antiseptics should be given such as octenidine solution or topical antibiotics, e. g., fusidic acid.

In addition, individually tailored antipruritic measures should be undertaken to eliminate pruritus; this includes treatment measures such as cutting the fingernails and, if necessary, even wearing cotton gloves. In some instances, instruments such as brushes are used to combat the itching.

When determining a treatment concept, individual factors should be taken into consideration and a multimodal concept consisting of topical, systemic therapy should be laid out.

### Topical antipruritic therapies

#### Topical corticosteroids

Potent topical corticosteroids are frequently prescribed. Drugs with a favorable risk-to-side effect profile such as mometasone furoate or methylprednisolone aceponate should be used. Especially at the beginning of therapy, dosages may be given more frequently than approved for the drug.

A highly effective method of interrupting the itch-scratch cycle, and thus the probable development of prurigo nodules, is application of topical corticosteroids under occlusion (Meyers 1989).

Intralesional application of corticosteroids has to be carefully considered. A triamcinolone acetonide suspension 10-40 mg/ml may be given, possibly with a local anesthetic. Improper use of intralesional corticosteroids can lead to atrophy or systemic side effects.

#### Calcineurin inhibitors

The antipruritic effect of topical calcineurin inhibitors has been shown in various studies (Ständer et al. 2003). In prurigo nodularis a case series has reported successful topical use of the calcineurin inhibitor tacrolimus (Lee et al. 2005).

As with topical corticosteroids, the effects of calcineurin inhibitors can be enhanced if they are applied under occlusion.

When prescribing calcineurin inhibitors, patients should be informed of side effects and necessary precautions such as avoiding UV light exposure including phototherapy.

The antipruritic effect of calcineurin inhibitors can possibly be explained by their anti-inflammatory effect and direct effect on nerve fibers (Ständer et al. 2003).

#### Vitamin D<sub>3</sub> analogues

There are several reports on the efficacy of topical therapy with vitamin D<sub>3</sub> analogues (calcipotriol, tacalcitol) in prurigo nodularis (Katayama et al. 1996; Wong et al. 2000). The mechanism of action of vitamin D<sub>3</sub> analogues in pruriginous lesions has not yet been fully elucidated, however.

#### Menthol and polidocanol

Topical antipruriginous agents for temporary reduction of pruritus include menthol (0.5-2%), urea (2-10%), and polidocanol (3-5%) in stage-adapted bases.

#### Capsaicin

Topical capsaicin therapy is an effective therapy, although there are only retrospective and uncontrolled clinical studies available on its use. Studies have shown that topical capsaicin can reduce pruritus and lead to remission of prurigo nodules (Reimann et al. 2000; Ständer et al. 2001; Tupker et al. 1992).

Topical capsaicin acts by desensitizing sensory nerve fibers and interrupting transmission of cutaneous pruritus and burning pain.

Capsaicin is given in gradually increasing doses (0.025% - 0.05% - 0.075% - 0.1%). In prurigo nodularis, concentrations of up to 0.3% may be necessary. When starting treatment, erythema, pruritus, and burning can occur. These side effects usually resolve, however, after three to five days. Frequent application is important, several times a day (i. e., 3-6 times). Excoriations should be adequately treated prior to beginning treatment in order to avoid excessive burning upon application of capsaicin cream. Capsaicin usually takes effect within a few days.



### Cannabinoid agonists

Topical use of the cannabinoid agonists N-palmitoylethanolamine (PEA) in a cream base has been reported as an effective and well-tolerated drug in therapy of pruriginous diseases such as prurigo nodularis (Ständer et al. 2006).

The rationale behind the use of cannabinoid agonists is knowledge of the expression of cannabinoid receptors on cutaneous sensory nerves.

### Phototherapy

Different phototherapy procedures can reduce pruritus and thereby improve prurigo nodularis. Phototherapy may be necessary if there are contraindications to topical or systemic drugs, or if the patient has pre-existing disease or is using other medications that prohibit their use, or during pregnancy. Among the methods described in the literature as effective for phototherapy in prurigo nodularis are broadband UVB (Divekar et al. 2003), narrow band UVB (Clark et al. 1998; Gambichler et al. 2005; Saraceno et al. 2008; Tamagawa-Mineoka et al. 2007), narrow band UVB in combination with thalidomide (Ferrandiz et al. 1997), UVA-1 phototherapy (Rombold et al. 2008), bath PUVA (Divekar et al. 2003; Väättäinen et al. 1997), and systemic PUVA (Divekar et al. 2003).

It is believed that due to inhibition of pro-inflammatory mediators, induction of anti-inflammatory and immunosuppressive factors as well as antiproliferative effects, pruritus is reduced in inflammatory skin disorders. Recent studies suggest that there is UVB-induced apoptosis of mast cells (Szepietowski et al. 2002).

### Systemic antipruritic therapies

#### Antihistamines

Among the most important systemic antipruriginous agents are oral antihistamines. Systemic antihistamines are especially effective if pruritus is caused by histamine (Krause et al. 1983). Yet because this is not always the case in prurigo nodularis, antihistamines may be insufficient or only able to reduce symptoms to a limited extent.

Available drugs include first generation sedating H<sub>1</sub>-antihistamines such as clemastine, hydroxyzine and promethazine, which can be given to help the patient sleep better. Non-sedating or only mildly sedating second generation H<sub>1</sub>-antihistamines include cetirizine, levocetirizine, loratadine, desloratadine, azelastine, fexofenadine, ebastine, or rupatadine. Although combining different antihistamines has been controversially discussed, for a sufficient antipruritic effect, higher dosages than approved for the drug are often necessary (Schulz et al. 2009). The patient should be informed of this and about known side effects of antihistamines.

An antipruritic effect has also been shown for azelastine which animal studies have attributed to blocking of leukotriene B<sub>4</sub> and substance P (Andoh et al. 2002).

#### Cyclosporine

Successful use of cyclosporine in prurigo nodularis was reported in the 1990s (Berth-Jones et al. 1995; Koblenzer 1996).

Current data underscore the antipruritic effect of cyclosporine in prurigo nodularis: one paper reported that more than 90% of patients with prurigo nodularis had a significant response under therapy with a 3-5 mg cyclosporine microemulsion per kg body weight daily (Siepmann et al. 2008). Cyclosporine may also be used in patients with severe underlying atopic dermatitis; however, blood pressure, blood count, transaminase and renal function must be routinely checked.

Cyclosporine inhibits the function of lymphocytes as well as mast cells and can thus suppress the development of pruritus.

#### Anticonvulsant agents

Along with an analgesic effect, the anticonvulsant drug gabapentin also has an antipruritic effect.

A recent study reported the effective use of gabapentin in therapy of prurigo nodularis. The daily dose was from 300 mg to 1 200 mg maximum (Dereli et al. 2008).

The mechanism of action of gabapentin has not been completely explained. Presumably there is membrane stabilization of the nerves due to a blockade of calcium channels, inhibition of synthesis of the neurotransmitter glutamate, or increased GABAergic inhibitory mechanisms (Scheinfeld 2003; Winhoven et al. 2004).

#### Antidepressants

Antidepressants should only be prescribed on the basis of psychosomatic or psychiatric diagnosis, taking into consideration related side effects of the respective drug.

Several studies have reported an antipruritic effect of various antidepressants: for instance, the tetracyclic antidepressant mirtazapine, at a dose of 15-30 mg/day, has been reported to have a positive influence on pruritus of various causes (Davis et al. 2003).

The serotonin uptake inhibitor paroxetine is also considered to be effective against pruritus of various causes (Biondi et al. 2000; Ständer et al. 2009; Tefferi et al. 2002; Zyllicz et al. 1998).

The serotonin receptor antagonist ondansetron has also been shown to be effective against pruritus in various skin disorders including prurigo simplex (Zenker et al. 2003).

### Opioid receptor antagonist

Pruritus may also be triggered or exacerbated by opioids, which is attributed to their binding to peripheral and central opioid receptors. Antagonizing opioids, on the other hand, can suppress local and systemic pruritus.

Naltrexone is a newer opioid receptor antagonist with a long-lasting, selective blockade of  $\mu$ -opioid receptors. One study showed that within a few days there was a significant decrease in pruritus under naltrexone 50 mg/day orally and including healing of prurigo nodularis lesions (Metze et al. 1999).

Contraindications for naltrexone use include severe liver and kidney disease, acute hepatitis, and opioid misuse. Adverse effects can make it necessary to discontinue therapy. Tachyphylaxis can occur and can be counteracted by increasing the dose.

### Thalidomide

The first reports on the successful use of thalidomide in prurigo nodularis were published in the 1970s and were subsequently confirmed during the following years (Alfadley et al. 2003; Broek 1980; Sheskin 1975; Winkelmann et al. 1984). Although thalidomide has experienced something of a renaissance, it should be used with caution given the risk of birth defects as well as its neurotoxic side effect profile.

Thalidomide is given at a dosage between 100 mg/day and a maximum of 400 mg/day. A lower maintenance dose may be sufficient.

### Roxithromycin with tranilast

There are three reports on the successful use of combination therapy with roxithromycin at a dosage of 300 mg/day with tranilast (N-(3,4-dimethoxycinnamoyl)) in a dosage of 200 mg/day in patients with prurigo nodularis (Horiuchi et al. 2006). It is believed that the macrolide antibiotic roxithromycin has immunosuppressant properties; for tranilast it is believed that the drug inhibits the proliferation of fibroblasts.

### Other therapy procedures

#### Cryosurgery

Cryosurgery is a widely used option in treatment of prurigo nodules.

The use of liquid nitrogen in an open spray procedure applied to the nodules can, depending on their size, vary from 10-30 seconds with two to four "freeze-thaw cycles." It can take up to four weeks until the treated nodules heal. Residual scarring can occur. After cryosurgery, patients can be pruritus-free for up to three months (Waldinger et al. 1984).

Combination therapy with cryosurgery, intralesional triamcinolone acetonide 40 mg/ml and lidocaine 1% is another effective treatment method in prurigo nodularis (Stoll et al. 1983).

#### Laser

There is little information available on the results of laser therapy in prurigo nodularis. Laser is appropriate for solitary, especially treatment-refractory lesions. One patient with prurigo nodularis was reportedly successfully treated in several treatment sessions with pulsed dye laser at a wavelength of 585 nm and an energy density of 6.5 J/cm<sup>2</sup> (Woo et al. 2000).

Pulsed dye laser emits a wavelength which is close to the absorption maximum of oxygenated hemoglobin and causes targeted thermal damage of dermal vessels.

#### Psychotherapy

Psychosomatic and psychiatric treatment are an important part of therapy in patients with prurigo nodularis if psychological factors or if a psychosomatic or psychiatric disorder are suspected or diagnosed. In addition, standardized educational measures, e. g., the working group on neurodermatitis education (AGNES), are available which teach relaxation techniques, for instance, to help patients successfully manage what is often a chronic, relapsing disorder.

### Keywords

Prurigo nodularis, pruritus, pathogenesis, diagnostic procedures, therapy

### References

- ABADIA MOLINA F, BURROWS NP, JONES RR, TERENGI G, POLAK JM.** Increased sensory neuropeptides in nodular prurigo: a quantitative immunohistochemical analysis. *Br J Dermatol* 1992; 127: 344–51.
- ACCIOLY-FILHO JW, NOGUEIRA A, RAMOS-E-SILVA M.** Prurigo nodularis of Hyde: an update. *J Eur Acad Dermatol Venereol* 2000; 14: 75–82.
- ALFADLEY A, AL-HAWSAWI K, THESTRUP-PEDERSEN K, AL-ABOUD K.** Treatment of prurigo nodularis with thalidomide: a case report and review of the literature. *Int J Dermatol* 2003; 42: 372–5.
- AMER A, FISCHER H.** Prurigo nodularis in a 9-year-old girl. *Clin Pediatr (Phila)* 2009; 48: 93–5.
- ANDOH T, KURAISHI Y.** Inhibitory effects of azelastine on substance P-induced itch-associated response in mice. *Eur J Pharmacol* 2002; 436: 235–9.
- BERTH-JONES J, SMITH SG, GRAHAM-BROWN RAC.** Nodular prurigo responds to cyclosporin. *Br J Dermatol* 1995; 132: 795–9.
- BIONDI M, ARCANGELI T, PETRUCCI RM.** Paroxetine in a case of psychogenic pruritus and neurotic excoriations. *Psychother Psychosom* 2000; 69: 165–6.
- BRAUN-FALCO O, PLEWIG G, WOLFF HH, BURGDORF WHC, LANDTHALER M (Hrsg).** *Dermatologie und Venerologie*. Berlin, Heidelberg, New York: Springer 2005.
- BRENNINKMEIJER EE, SCHRAM ME, LEEFLANG MM, BOS JD, SPULS PI.** Diagnostic criteria for atopic dermatitis: a systematic review. *Br J Dermatol* 2008; 158: 754–65.
- BROEK H VAN DEN.** Treatment of prurigo nodularis with thalidomide. *Arch Dermatol* 1980; 116: 571–2.
- CLARK AR, JORIZZO JL, FLEISCHER AB.** Papular dermatitis (subacute prurigo, »itchy red bump« disease): pilot study of phototherapy. *J Am Acad Dermatol* 1998; 38: 929–33.
- COWAN MA.** Neurohistological changes in prurigo nodularis. *Arch Dermatol* 1964; 89: 754–8.
- DAVIS MP, FRANSEN JL, WALSH D, ANDRESEN S, TAYLOR S.** Mirtazapine for pruritus. *J Pain Symptom Manage* 2003; 25: 288–91.
- DERELI T, KARACA N, INANIR I, OZTÜRK G.** Gabapentin for the treatment of recalcitrant chronic prurigo nodularis. *Eur J Dermatol* 2008; 18: 85–6.
- DILLON SR, SPRECHER C, HAMMOND A, BILSBOROUGH J, ROSENFELD-FRANKLIN M, PRESNELL SR, HAUGEN HS, MAURER M, HARDER B, JOHNSTON J, BORT S, MUDRI S, KUIJPER JL, BUKOWSKI T, SHEA P, DONG DL, DASOVICH M, GRANT FJ, LOCKWOOD L, LEVIN SD, LEICHEL C, WAGGIE K, DAY H, TOPOUZIS S, KRAMER J, KUESTNER R, CHEN Z, FOSTER D, PARRISH-NOVAK J, GROSS JA.** Interleukin 31, a cytokine produced by activated T cells, induces dermatitis in mice. *Nat Immunol*. 2004; 5: 752–60. Erratum in: *Nat Immunol* 2005; 6: 114.
- DIVEKAR PM, PALMER RA, KEEFE M.** Phototherapy in nodular prurigo. *Clin Exp Dermatol* 2003; 28: 99–100.
- FERRÁNDIZ C, CARRASCOSA JM, JUST M, BIELSA I, RIBERA M.** Sequential combined therapy with thalidomide and narrow-band (TL01) UVB in the treatment of prurigo nodularis. *Dermatology* 1997; 195: 359–61.
- GAMBICHLER T, BREUCKMANN F, BOMS S, ALTMAYER P, KREUTER A.** Narrowband UVB phototherapy in skin conditions beyond psoriasis. *J Am Acad Dermatol* 2005; 52: 660–70.
- GALLO R, PARODI A, REBORA A.** Pemphigoid nodularis. *Br J Dermatol* 1993; 129: 744–5.
- HEBRA F VON.** *Traité pratique des maladies de la peau*. Paris 1854; 479.
- HORIUCHI Y, BAE S, KATAYAMA I.** Uncontrollable prurigo nodularis effectively treated by roxithromycin and tranilast. *J Drugs Dermatol* 2006; 5: 363–5.
- HYDE JN.** A practical treatise on disease of the skin, for the use of students and practitioners. Prurigo nodularis. In: Hyde JN, Montgomery FH. *A Practical Treatise on Diseases of the Skin for the Use of Students and Practitioners*. 3rd edn. Philadelphia, PA: Lea & Febiger 1909; 174–5.
- IDO T, TAKASHIMA W, KIYOHARA T, KUMAKIRI M, KANIWA M.** Prurigo nodularis occurred in a patient with an allergy to pyridine derivative in desk mat. *Contact Dermatitis* 2008; 58: 250–1.
- JOHANSSON O, LIANG Y, EMTESTAM L.** Increased nerve growth factor and tyrosine kinase A-like immunoreactivities in prurigo nodularis – an exploration of the cause of neurohyperplasia. *Arch Dermatol Res* 2002; 293: 614–9.
- KATAYAMA I, MIYAZAKI Y, NISHIOKA K.** Topical vitamin D<sub>3</sub> (tacalcitol) for steroid-resistant prurigo. *Br J Dermatol* 1996; 135: 237–40.
- KERL H, GARBE C, CERRONI L, WOLFF HH (Hrsg).** *Histopathologie der Haut*. Berlin, Heidelberg, New York: Springer 2003.
- KOBLENZER CS.** Treatment of nodular prurigo with cyclosporin (treat the disease, not just the symptoms). *Br J Dermatol* 1996; 135: 330–1.
- KRAUSE L, SHUSTER S.** Mechanism of action of antipruritic drugs. *Br Med J (Clin Res Ed)* 1983; 287: 1199–200.
- LEE HH, STERRY W, WORM M.** Wirksamkeit von Tacrolimus-0,1%-Salbe bei Prurigoerkrankungen. *J Dtsch Dermatol Ges* 2005; 3: 690–4.
- LEE MR, SHUMACK S.** Prurigo nodularis: a review. *Australas J Dermatol* 2005; 46: 211–20.
- LIANG Y, HEILBORN JD, MARCUSON JA, JOHANSSON O.** Increased NGFr immunoreactive, dermal nerve fibers in prurigo nodularis. *Eur J Dermatol* 1996; 6: 563–7.
- LIANG Y, MARCUSON JA, JACOBI HH, HAAK-FRENDSCHE M, JOHANSSON O.** Histamine-containing mast cells and their relationship to NGFr-immunoreactive nerves in prurigo nodularis: a reappraisal. *J Cutan Pathol* 1998; 25: 189–98.
- MASSA MC, CONOLLY SM.** Bullous pemphigoid with features of prurigo nodularis. *Arch Dermatol* 1982; 118: 937–9.
- METZ M, STÄNDER S.** Chronischer Pruritus. *CME Dermatol* 2008; 3: 124–43.

- METZE D, REIMANN S, BEISSERT S, LUGER T.** Efficacy and safety of naltrexone, an oral opiate receptor antagonist, in the treatment of pruritus in internal and dermatological diseases. *J Am Acad Dermatol* 1999; 41: 533–9.
- MEYERS LN.** Use of occlusive membrane in the treatment of prurigo nodularis. *Int J Dermatol* 1989; 28: 275–6.
- NERI S, RACITI C, D'ANGELO G, IERNA D, BRUNO CM.** Hyde's prurigo nodularis and chronic HCV hepatitis. *J Hepatol* 1998; 28: 161–4.
- REIMANN S, LUGER T, METZE D.** Topische Anwendung von Capsaicin in der Dermatologie zur Therapie von Juckreiz und Schmerz. *Hautarzt* 2000; 51: 164–172.
- ROENIGK RK, DAHL MV.** Bullous pemphigoid and prurigo nodularis. *J Am Acad Dermatol* 1986; 14: 944–7.
- ROMBOLD S, LOBISCH K, KATZER K, GRAZZIOTIN TC, RING J, EBERLEIN B.** Efficacy of UVA1 phototherapy in 230 patients with various skin diseases. *Photodermatol Photoimmunol Photomed* 2008; 24: 19–23.
- ROSS JS, MACKEE PH, SMITH NP, SHIMIZU H, GRIFFITHS WA, BHOGAL BS, BLACK MM.** Unusual variants of pemphigoid: from pruritus to pemphigoid nodularis. *J Cutan Pathol* 1992; 19: 212–6.
- ROWLAND PAYNE CME, WILKINSON JD, MCKEE PH, JURECKA W, BLACK MM.** Nodular prurigo – a clinico-pathological study of 46 patients. *Br J Dermatol* 1985; 113: 431–9.
- SARACENO R, NISTICÒ SP, CAPRIOTTI E, DE FELICE C, RHODES LE, CHIMENTI S.** Monochromatic excimer light (308 nm) in the treatment of prurigo nodularis. *Photodermatol Photoimmunol Photomed* 2008; 24: 43–5.
- SCHEINFELD N.** The role of gabapentin in treating diseases with cutaneous manifestations and pain. *Int J Dermatol* 2003; 42: 491–5.
- SCHNEIDER G, DRIESCH G, HEUFT G, EVERS S, LUGER TA, STÄNDER S.** Psychosomatic cofactors and psychiatric comorbidity in patients with chronic itch. *Clin Exp Dermatol* 2006; 31: 762–7.
- SCHNEIDER G, HOCKMANN J, STÄNDER S, LUGER TA, HEUFT G.** Psychological factors in prurigo nodularis in comparison with psoriasis vulgaris: results of a case-control study. *Br J Dermatol* 2006; 154: 61–6.
- SCHULZ S, METZ M, SIEPMANN D, LUGER TA, MAURER M, STÄNDER S.** Antipruritic efficacy of a high-dosage antihistamine therapy. Results of a retrospectively analysed case series. *Hautarzt* 2009; 60: 564–8.
- SHESKIN J.** Treatment of prurigo nodularis Hyde using thalidomide. *Hautarzt* 1975; 26: 215–7.
- SIEPMANN D, LUGER TA, STÄNDER S.** Antipruritic effect of cyclosporine microemulsion in prurigo nodularis: results of a case series. *J Dtsch Dermatol Ges* 2008; 6: 941–6.
- SONKOLY E, MÜLLER A, LAUERMA AI, PIVARCSI A, SOTO H, KEMENY L, ALENIUS H, DIEU-NOSJEAN MC, MELLER S, RIEKER J, STEINHOFF M, HOFFMANN TK, RUZICKA T, ZLOTNIK A, HOMEY B.** IL-31: a new link between T cells and pruritus in atopic skin inflammation. *J Allergy Clin Immunol*. 2006; 117: 411–7.
- STÄNDER S, BÖCKENHOLT B, SCHÜRMEYER-HORST F, WEISHAUPT C, HEUFT G, LUGER TA, SCHNEIDER G.** Treatment of chronic pruritus with the selective serotonin re-uptake inhibitors paroxetine and fluvoxamine: results of an open-labelled, two-arm proof-of-concept study. *Acta Derm Venereol* 2009; 89: 45–51.
- STÄNDER S, LUGER TA.** Antipruritic effects of pimecrolimus and tacrolimus. *Hautarzt* 2003; 54: 413–7.
- STÄNDER S, LUGER T, METZE D.** Treatment of prurigo nodularis with topical capsaicin. *J Am Acad Dermatol* 2001; 44: 471–8.
- STÄNDER S, MOORMANN C, SCHUMACHER M, BUDDENKOTTE J, ARTUC M, SHPACOVITCH V, BRZOSKA T, LIPPERT U, HENZ BM, LUGER TA, METZE D, STEINHOFF M, STEINHOFF M.** Expression of vanilloid receptor subtype 1 in cutaneous sensory nerve fibers, mast cells, and epithelial cells of appendage structures. *Exp Dermatol* 2004; 13: 129–39.
- STÄNDER S, REINHARDT HW, LUGER TA.** Topical cannabinoid agonists. An effective new possibility for treating chronic pruritus. *Hautarzt* 2006; 57: 801–7.
- STÄNDER S, SCHÜRMEYER-HORST F, LUGER TA, WEISSHAAR E.** Treatment of pruritic diseases with topical calcineurin inhibitors. *Ther Clin Risk Manag* 2006; 2: 213–8.
- STÄNDER S, STREIT M, DARSOW U, NIEMEIER V, VOGELSANG M, STÄNDER H, GIELER U, GOLLNICK H, METZE D, WEISSHAAR E.** Diagnostisches und therapeutisches Vorgehen bei chronischem Pruritus. *J Dtsch Dermatol Ges* 2006; 4: 350–70.
- STOLL DM, FIELDS JP, KING LE.** Treatment of prurigo nodularis: use of cryosurgery and intralesional steroids plus lidocaine. *J Dermatol Surg Oncol* 1983; 9: 922–4.
- SZEPIETOWSKI JC, MORITA A, TSUJI T.** Ultraviolet B induces mast cell apoptosis: a hypothetical mechanism of ultraviolet B treatment for uraemic pruritus. *Med Hypotheses* 2002; 58: 176–170.
- TAMAGAWA-MINEOKA R, KATOH N, UEDA E, KISHIMOTO S.** Narrow-band ultraviolet B phototherapy in patients with recalcitrant nodular prurigo. *J Dermatol* 2007; 34: 691–5.
- TANAKA M, AIBA S, MATSUMURA N, AOYAMA H, TAGAMI H.** Prurigo nodularis consists of two distinct forms: early-onset atopic and late-onset non-atopic. *Dermatology* 1995; 190: 269–76.
- TANI M, MURATA Y, MASAKI H.** Pemphigoid nodularis. *J Am Acad Dermatol* 1989; 21: 1099–104.
- TEFFERI A, FONSECA R.** Selective serotonin reuptake inhibitors are effective in the treatment of polycythemia vera-associated pruritus. *Blood* 2002; 99: 2627.
- TORCHIA D, CAPRONI M, DEL BIANCO E, COZZANI E, KETABCHI S, FABBRI P.** Linear IgA disease presenting as prurigo nodularis. *Br J Dermatol* 2006; 155: 479–80.
- TUPKER RA, COENRAADS PJ, VAN DER MEER JB.** Treatment of prurigo nodularis, chronic prurigo, neurodermatitis circumscripta with topical capsaicin. *Acta Derm Venereol* 1992; 72: 463–5.
- VÄÄTÄINEN N, HANNUKSELA M, KARVONEN J.** Local phototherapy in nodular prurigo. *Acta Derm Venereol* 1979; 59: 544–7.
- VAIDYA DC, SCHWARTZ RA.** Prurigo nodularis: a benign dermatosis derived from a persistent pruritus. *Acta Dermatol Croat* 2008; 16: 38–44.

**WALDINGER TP, WONG RC, TAYLOR WB, VOORHEES JJ.**

Cryotherapy improves prurigo nodularis. *Arch Dermatol* 1984; 120: 1598–600.

**WALLENGREN J.** Prurigo: diagnosis and management. *Am J Clin Dermatol* 2004; 5: 85–95.

**WINHOVEN SM, COULSON IH, BOTTOMLEY WW.** Brachioradial pruritus: response to treatment with gabapentin. *Br J Dermatol* 2004; 150: 786–7.

**WINKELMANN RK, CONNOLLY SM, DOYLE JA, GONÇALVES AP.** Thalidomide treatment of prurigo nodularis. *Acta Derm Venereol* 1984; 64: 412–7.

**WONG SS, GOH CL.** Double-blind, right/left comparison of calcipotriol ointment and betamethasone ointment in the treatment of prurigo nodularis. *Arch Dermatol* 2000; 136: 807–8.

**WOO PN, FINCH TM, HINDSON C, FOULDS IS.** Nodular prurigo successfully treated with the pulsed dye laser. *Br J Dermatol* 2000; 143: 215.

**ZELICKSON BD, MCEVOY MT, FRANSWAY AF.** Patch testing in prurigo nodularis. *Contact Dermatitis* 1989; 20: 321–5.

**ZENKER S, SCHUH T, DEGITZ K.** Therapy of pruritus associated with skin diseases with the serotonin receptor antagonist ondansetron. *J Dtsch Dermatol Ges* 2003; 1: 705–10.

**ZYLICZ Z, SMITS C, KRAJNIK M.** Paroxetine for pruritus in advanced cancer. *J Pain Symptom Manage* 1998; 16: 121–4.





Prof. Dr. med. Bernhard Homey

Hautklinik  
Universitätsklinikum Düsseldorf  
Moorenstraße 5  
40225 Düsseldorf  
Germany

Professor Dr. Homey, M.D., studied medicine at the University of Düsseldorf, where he also completed his specialization in Dermatology and Venerology. After clinical and research visits to the University of California, San Francisco, he conducted his post-doctoral work from 1998 to 2001 at DNAX Research Institute in Palo Alto, CA. After completing his post-doctorate in 2003 he was appointed to a C3 professorship in 2004 for dermatology University of Düsseldorf. Since then he has headed the areas of allergy and autoimmune disease. Since May of 2006 he has been the acting chairman of the Department of Dermatology at the University of Düsseldorf.

His main research focus is on the pathogenetic role of cytokines and chemokines in allergy, autoimmunity, as well as tumor progression and metastasis. A particular area of interest in his research is to better understand the mechanisms underlying the development of pruritus.



Dr. med. Sibylle Eigelshoven

Hautklinik  
Universitätsklinikum Düsseldorf  
Moorenstraße 5  
40225 Düsseldorf  
Germany

Dr. Sibylle Eigelshoven, M.D., is specialized in dermatology and venerology with additional qualifications in allergology, andrology, and natural healing methods. She is employed at the Department of Dermatology at the University of Düsseldorf Hospital. Her clinical work focuses on mainly the diagnosis and therapy of allergic diseases.

#### Conflict of interest

The authors declare that there is no conflict of interest as defined by the guidelines of the International Committee of Medical Journal Editors (ICMJE; [www.icmje.org](http://www.icmje.org)).

#### Manuscript information

Submitted on: 19.05.2009

Accepted on: 26.08.2009

# CME-Continuing Medical Education

## Prurigo nodularis

### Question 1

Which of the following is *not* a clinical characteristic of prurigo nodularis:

- a. Predominantly symmetrical pattern of distribution of lesions
- b. Almost no pruritus
- c. Papules and nodules as primary lesions
- d. Predilection sites are the extensor aspects of the extremities
- e. Excoriations, crusts, and scars are secondary lesions

### Question 2

Which of the following statements is true of prurigo nodularis?

- a. The disorder predominantly affects children.
- b. There is a high rate of spontaneous healing.
- c. Men are affected more often than women.
- d. There is never atopic diathesis.
- e. The disease is highly refractory to treatment.

### Question 3

Which of the following is *not* a histopathological criterium for a prurigo nodule:

- a. Hyperkeratosis
- b. Acanthosis
- c. Proliferation of nerve fibers
- d. Infiltrate with lymphocytes, eosinophilic granulocytes, and mast cells
- e. Munro microabscesses

### Question 4

Initial basic diagnostic procedures do *not* include:

- a. Blood differential
- b. Transaminase levels
- c. MRI
- d. Hepatitis serology
- e. Patient history and physical examination

### Question 5

Which cytokine is present in significantly larger amounts in prurigo nodularis lesions?

- a. IL-17
- b. IL-33
- c. IL-31
- d. IL-22
- e. IL-23

### Question 6

Which of the following statements *least* applies to prurigo nodularis?

- a. Chronic mechanical skin trauma plays a central role.
- b. Although an inflammatory reaction is visible, fibroblast activity is normal.
- c. Mast cells in prurigo nodularis lesions are enlarged and occasionally have a dendritic appearance.
- d. Nerve fibers express increased levels of "nerve growth factor"(NGF)-receptor p75.
- e. There are signs of keratinocyte activation.

### Question 7

Which is the best answer? Nerve fibers in prurigo nodularis produce increased amounts of:

- a. CGRP
- b. IL-4
- c. IL-31
- d. Bradykinin
- e. Cannabinoide

### Question 8

Which of the following statements on therapy of prurigo nodularis is the most accurate?

- a. Phototherapy is no longer used.
- b. The main goal of treatment is to stop the pruritus.
- c. An accompanying psychosomatic therapy is not especially important.
- d. Regular use of an emollient is not needed.
- e. Treatment is limited to topical or systemic drugs only.

### Question 9

Which of the following statements on topical capsaicin is true?

- a. Capsaicin has no known side effects.
- b. The initial concentration is at least 1%.
- c. Capsaicin is given in gradually increasing doses.
- d. Once daily application is sufficient.
- e. It takes several months for the drug to take effect.

**Question 10**

Which of the following statements on the use of cyclosporine in prurigo nodularis is *not* true?

- a. Reports on the successful use of cyclosporine in the treatment of prurigo nodularis are still lacking.
- b. The dosage is 3-5 mg cyclosporine/kg body weight/day.
- c. Regular blood pressure and laboratory tests should be performed during therapy.
- d. Cyclosporine inhibits the activation of inflammatory cells in the skin.
- e. Patients usually respond to therapy within a few weeks.